

PROSPECTIVE EVALUATION OF A ONE-STAGE ESOPHAGEAL BALLOON DILATION FEEDING TUBE (EBDFT) FOR BENIGN ESOPHAGEAL STRICTURES IN DOGS: INITIAL RESULTS IN 6 DOGS

Weisse, C., Berent, A.

Interventional Radiology and Interventional Endoscopy Service, The Animal Medical Center, New York, NY

INTRODUCTION:

Dysphagia due to benign esophageal strictures is an important cause of morbidity and mortality in veterinary medicine. While intrinsic benign esophageal strictures most commonly occur as a result of esophagitis following gastroesophageal reflux, any significant chemical or mechanical injury to the esophageal mucosa can potentially result in formation of a stricture. The impact of esophageal strictures on pets and their owners is significant; they can be costly to treat and often associated with a poor prognosis.

The goal of treating benign esophageal strictures (BES) is to reduce the frequency of regurgitation to the extent that oral feeding can be used to maintain nutrition and hydration. The current mainstays of mechanical dilation therapy include endoscopic-guided balloon dilation and/or bougienage. A "good" outcome has been reported following balloon dilation (74-88%) and bougienage (74-78%) for benign esophageal strictures in dogs. Authors of these studies report that a "successful outcome" often requires two or greater dilation therapies; these treatments are performed under general anesthesia, which can encourage further esophageal reflux, and can be costly. In addition, a "good" outcome is often defined as requiring a soft food or a gruel, as the stricture often remains to some degree. Few (likely under 20%) of these animals ever regain normal feeding regimens.

Esophageal stenting has been attempted as a possible one-stage solution for BES. Unfortunately, the authors' experience with esophageal stenting has been disappointing; however these procedures were performed in patients with intractable recurrent benign esophageal strictures (RBES) defined as >3 dilation procedures with stricture recurrence. The major advantage of the presence of a stent is the consistent dilation performed, not permitting the stricture to reform, or the edges of the torn mucosa to meet. Unfortunately the stents are often not well tolerated by the patients, with subsequent high rates of dysphagia, gagging and discomfort.

From review of the data available in previous reports, it seems the ideal treatment for benign esophageal strictures would be to provide consistent (or nearly consistent) dilation of the stricture to prevent reform, but also permit easy removal of the device if it is not well tolerated, or when the stricture has been effectively treated. The primary purpose of the study performed here is to determine if a one-stage esophageal balloon dilation feeding tube (EBDFT) could be an effective, single-procedure alternative to repeated balloon dilation procedures for the treatment of benign esophageal strictures in dogs. To the authors' knowledge, no study to date has reported the clinical use of such a device for palliative management of benign esophageal strictures.

MATERIALS & METHODS :

Study Population

Dogs diagnosed with benign esophageal strictures were included following client consent; exclusion criteria included comorbidities preventing general anesthesia, or lack of follow-up communication. Dysphagia scores (TABLE 1) were obtained prior to, and following, placement of the EBDFT throughout the follow-up period.

Procedure

With the help of engineers at **Mila International Inc.**, we designed a non-compliant esophageal balloon dilation device mounted on a commercially available and commonly used esophageal feeding tube (FIGURE 1). The noncompliant balloon is covered with a compliant polyurethane balloon to help capture and constrict the noncompliant balloon contained inside to provide a low-profile device when it is not inflated. This device would be placed using a similar technique to that currently used for E-tube placement, and left in place for approximately one month (FIGURE 2). The owner performs twice daily balloon dilations at home (FIGURE 3) using predetermined air volumes and provides supplementation of food, water and medications through the tube if necessary. While stricture dilation can be uncomfortable in humans, the initial stricture effacement would occur under the initial anesthetic episode, so subsequent dilations would not be expected to be associated with discomfort. In-between the twice daily dilations, the balloon would be constrained permitting passage of normal food and liquid boluses during normal per os eating and drinking.

Dysphagia Score Sheet

A previously described and commonly used human "dysphagia score" of 0-4 was modified and used to determine outcome.

Score 0: Patients able to eat a normal diet with no dysphagia.
 Score 1: Patients able to swallow some solid foods (kibble or canned food).
 Score 2: Patients able to swallow only semi-solid foods (gruel).
 Score 3: Patients able to swallow liquids only.
 Score 4: Patients unable to swallow anything including saliva; total dysphagia.

A **DECREASE** in dysphagia score is considered a clinical improvement.

TABLE 1: Modified dysphagia score sheet used pre-operatively, and post-EBDFT placement.

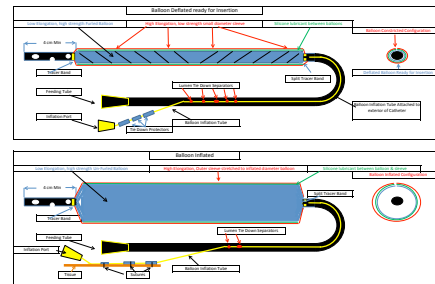


FIGURE 1: Diagram demonstrating deflated (above) and inflated (below) double balloon design. Outer compliant balloon maintains a low profile system within the esophageal lumen.

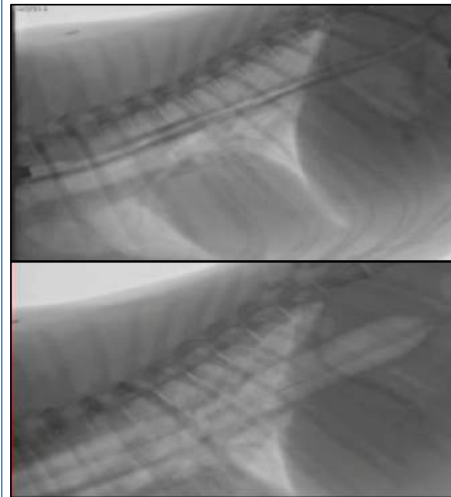


FIGURE 2: Lateral thoracic fluoroscopic images demonstrating EBDFT placement prior to (above) and during (below) full air inflation of the balloon. This distal stricture required placement of the EBDFT across the lower esophageal sphincter. In both dogs in which this distal placement was used, inflations were similarly tolerated and no long term ill effects were recognized.

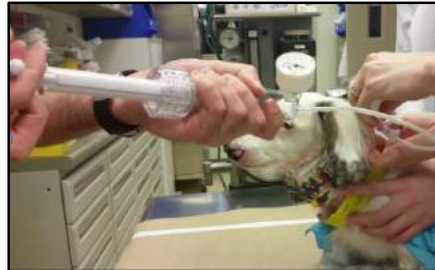

FIGURE 3: Awake EBDFT dilation being performed using a 60cc digitator and three-way stopcock. Temporary gagging, if present, is quickly relieved following rapid balloon deflation.

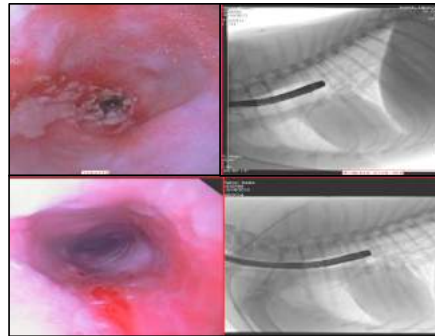


FIGURE 4: Endoscopic (left) and fluoroscopic (right) images during initial stricture evaluation at the time of EBDFT placement (above) and following removal of the EBDFT approximately 5 weeks later. Although there is some esophageal irritation from the chronic presence of the EBDFT in the bottom endoscopic image, complete stricture resolution is documented. This patient returned to normal eating (dysphagia score 3/4 pre-op to 0/4 following tube removal).

Case	Signalment	Cause	Previous Dilations	PRE-Dysphagia Score (0-4)	POST-Dysphagia Score (0-4)
1	8mon GSHP	OHE	2	3	1
2	11mon Gldn-Doodle	OHE	4	3	0
3	2yo LABR	Meds*	1	3	N/A
4	7yo LABR	Dental	10	3-5	2.5
5	2yo Chi	Parvo	1	2.5	0
6	5yo Dach	IVDD Sx	1	3	0

TABLE 2: Table demonstrating patient signalment, stricture etiology, number of previous balloon dilations performed prior to EBDFT placement, pre-EBDFT dysphagia score, and final dysphagia score at last follow-up. * Patient 3 was euthanized for other comorbidities prior to the EBDFT removal so a final dysphagia outcome could not be determined.

RESULTS:

Five female spayed and 1 male castrated dog ranging from 8 months to 7 years with confirmed esophageal strictures were included in this preliminary study. Causes for the strictures were confirmed following OHE surgery in 2, dental prophylaxis in 1, parvovirus infection in 1, IVDD surgery in 1, and suspected due to nausea following hydroxyurea therapy for polycythemia vera in 1. At the time of EBDFT placement, these patients received between 1 and 10 previous esophageal balloon dilations; 2 of which were considered recurrent (RBES) (>3 previous dilations). Prior to EBDFT placement, 5 dogs had dysphagia scores of 3/4 (only able to swallow liquids) and 1 had a score of 2.5/4 (able to tolerate gruels but continued to regurgitate).

All patients had endoscopic and fluoroscopic guided balloon dilation of the strictures as well as esophagoscopy before and after EBDFT placement. Five dogs had EBDFT placement via esophagostomy and one dog received pharyngostomy placement due to the proximal stricture location. There were no major intra-operative complications. All patients were discharged the same or the following day.

Post-operative complications occurred in 2 dogs including premature tube removal by the dog (1), and EBDFT failure requiring exchange (1). Two additional dogs had minor irritation or local infection at the tube sites that improved with cleaning and oral antibiotics. The prematurely removed tube was vomited up, presumably due to the location of the tube entering the stomach secondary to the very distal location of the stricture; this patient's final dysphagia score was 1/4 (able to swallow some kibble and canned food) following removal, and esophagoscopy demonstrated only a mild esophageal narrowing remaining. The EBDFT failure patient was ultimately euthanized due to severe comorbidities including polycythemia vera and other undiagnosed disease processes. Tubes remained in place between 14 and 56 days (FIGURE 4); Follow-up times ranged from 14 to 753 days (median 161 days, mean 274 days). Five of 6 dogs had improved dysphagia scores compared to pre-operative measurements (TABLE 2) and the sixth was ultimately euthanized due to comorbidities. While balloon inflations caused apparent minor, temporary discomfort in all patients, the owners felt it was well tolerated and instantaneously resolved following balloon deflation.

DISCUSSION/CONCLUSION:

Initial results suggest that the EBDFT may be an effective, single-procedure alternative to repeated balloon dilation procedures for the treatment of benign esophageal strictures in dogs. Preliminary results indicate complications including insertion site irritation/infection, inflation discomfort, and early tube failure (repaired) are relatively minor, self-limiting, and easily resolved. Performing the inflations does require dedicated owners. While there are certain size limitations currently, early prototypes have been updated. Newer double-lumen tubes will be available in a wider range of balloon diameters and lengths which will expand the range of patients that can be treated.

These first patients have demonstrated that the EBDFT has the potential for improved (and less expensive) outcomes in the treatment of BES as well as some RBES.

FOOTNOTES AND REFERENCES:

Harai BH, Johnson SE, Sherding RG. Endoscopically guided balloon dilatation of benign esophageal strictures in 6 cats and 7 dogs. *J Vet Intern Med* 1995;9:332-335.

Melendez LD, Tweed DC, Weyrauch EA, et al. Conservative therapy using balloon dilation for intramural, inflammatory esophageal strictures in dogs and cats: a retrospective study of 23 cases (1987-1997). *Eur J Comp Gastroenterol* 1998;3:31-36.

Leib MS, Dinnel H, Ward DL, et al. Endoscopic balloon dilation of benign esophageal strictures in dogs and cats. *J Vet Intern Med* 2001;15:547-552.

Adamama-Moraitou K.K., Rallis T.S., Prassinis N.N., et al. Benign esophageal stricture in the dog and cat: a retrospective study of 20 cases. *Can J Vet Res* 2002;66: 55-9.

Bissett SA, Davis J, Subler K, et al. Risk factors and outcome of bougienage for treatment of benign esophageal strictures in dogs and cats: 28 cases (1995-2004). *J Am Vet Med Assoc* 2009;235:844-850.

Lam N, Weisse C, Berent A, et al. Esophageal stenting for treatment of benign esophageal strictures in dogs. *J Vet Intern Med* 2013;27:1064-1070.