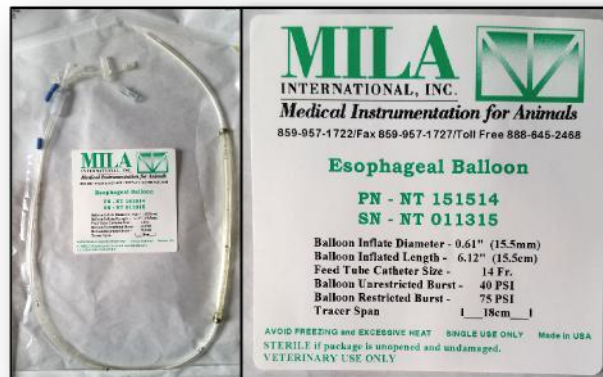

# Esophageal Balloon-Dilation Feeding Tube (EBDFT) Instructions For Use

(C. Weisse, A. Berent)

**BACKGROUND:** Dysphagia due to benign esophageal strictures is an important cause of morbidity and mortality in veterinary medicine. While intrinsic benign esophageal strictures most commonly occur as a result of esophagitis following gastroesophageal reflux, any significant chemical or mechanical injury to the esophageal mucosa can potentially result in formation of a stricture. The impact of esophageal strictures on pets and their owners is significant; they can be costly to treat and often associated with a poor prognosis.



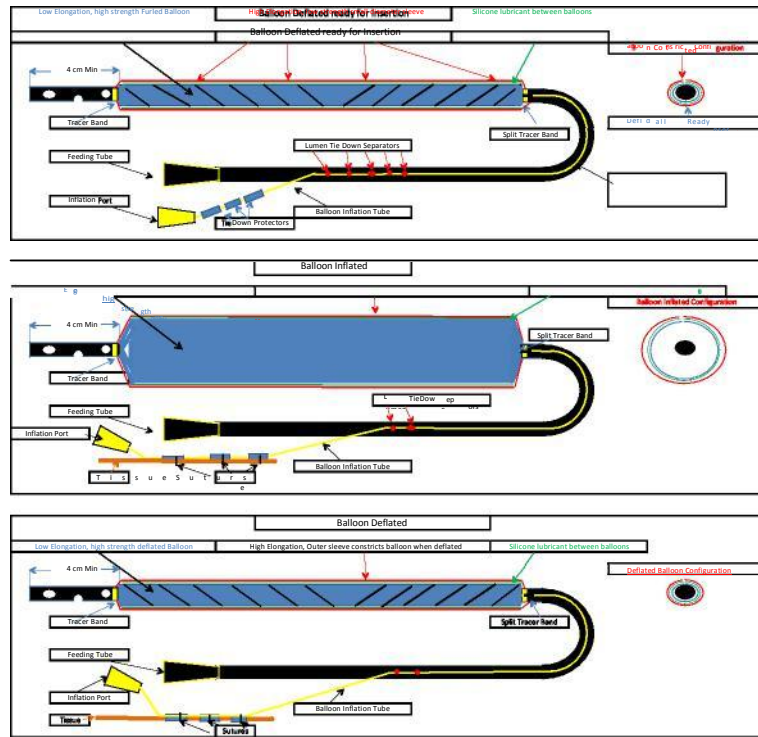
The goal of treating benign esophageal strictures (BES) is to reduce the frequency of regurgitation to the extent that oral feeding can be used to maintain nutrition and hydration. The current mainstays of mechanical dilation therapy include endoscopic--guided balloon dilation and/or bougienage. A “good” outcome has been reported following balloon dilation (74-88%) and bougienage (74-78%) for benign esophageal strictures in dogs. Authors of these studies report that a “successful outcome” often requires two or greater dilation therapies; these treatments are performed under general anesthesia, which can encourage further esophageal reflux, and can be costly. In addition, a “good” outcome is often defined as requiring a soft food or gruel, as the stricture often remains to some degree. Few (likely under 20%) of these animals ever regain normal feeding regimens.

Esophageal stenting has been attempted as a possible one---stage solution for BES. Unfortunately, the authors’ experience with esophageal stenting has been disappointing, however these procedures were performed in patients with intractable recurrent benign esophageal strictures (RBES) defined as >3 dilation procedures with stricture recurrence. The major advantage of the presence of a stent is the consistent dilation performed, not permitting the stricture to reform, or the edges of the torn mucosa to meet. Unfortunately the stents are often not well tolerated by the patients, with subsequent high rates of dysphagia, gagging and discomfort.

From review of the data available in previous reports, it seems the ideal treatment for benign esophageal strictures would be to provide consistent (or nearly consistent) dilation of the stricture to prevent reformation, but also permit easy removal of the device if it is not well tolerated, or when the stricture has been

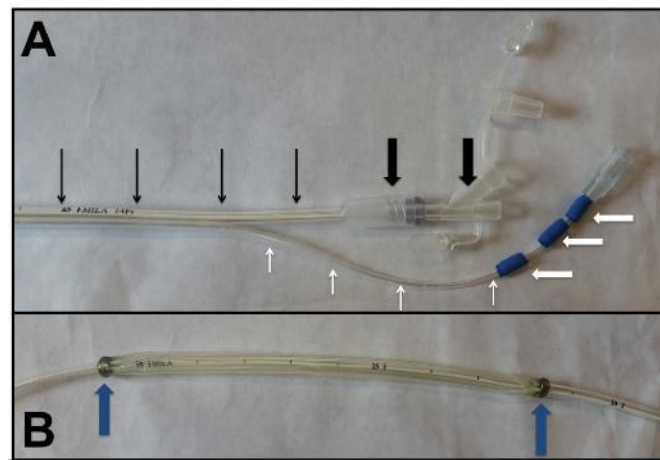
effectively treated. The one-stage esophageal balloon dilation feeding tube (EBDFT), otherwise known as the “Balloon-Tube” (or “B-Tube”) can be an effective, single-procedure alternative to repeated balloon dilation procedures for the treatment of benign esophageal strictures in dogs.

**INDICATIONS:** The B-Tube is indicated for dogs with either naïve (not previously dilated) or recurrent benign esophageal strictures (BES). The device has not yet been evaluated in cats although this is not currently considered a contraindication for use. Relative contraindication could include strictures within 1cm of the upper esophageal sphincter, however the B-Tube has been placed through a pharyngostomy incision for more cranially located strictures with success.



**FIGURE 1:** B-Tube double balloon design

**DESIGN AND USE:** The B-Tube is a non-compliant esophageal balloon dilation device mounted on a commercially available and commonly used esophageal feeding tube (FIGURE 1,2). The noncompliant balloon is covered with a compliant polyurethane balloon to help capture and constrict the noncompliant balloon contained inside to provide a low-profile device when it is not inflated. Once a BES has been diagnosed and traditionally balloon-dilated, the B-Tube is placed similarly to a standard esophageal feeding tube (E-Tube), with some technical differences. The owner performs twice daily



**FIGURE 2:** A. Two parts of the B-Tube – An esophageal feeding tube (black arrows) with a detachable Hub for feeding (Black block arrows). Balloon inflation tubing (white arrows) mounted alongside the E-Tube with blue tube compression guards (white block arrows) to prevent inflation tubing occlusion when securing in place with finger-trap sutures. B. Blue arrows mark the radio-opaque bands placed at the cranial and caudal balloon extent.

balloon dilations at home, in their unsedated pet, using predetermined air volumes. This tube can also provide supplementation of food, water and medications through the tube, if necessary. While stricture dilation can be uncomfortable in humans, the initial stricture effacement would occur under the initial anesthetic episode, so subsequent dilations would not be expected to be associated with discomfort. In-between the daily dilation procedures, the balloon would be self-constrained permitting passage of normal food and liquid boluses during normal per os eating and drinking. The B-Tube is typically removed approximately 4-6 weeks later, often under general anesthesia for repeat esophagoscopy to confirm stricture resolution (alternatively, the B-Tube can be removed in the awake patient).

**EXPECTATIONS:** Initial results suggest that the B-TUBE can be an effective, single-procedure alternative to repeated balloon dilation procedures for the treatment of benign esophageal strictures in dogs. Preliminary results indicate minor complications including: insertion site irritation/infection, inflation discomfort, and early tube failure (repaired). All of these complications were relatively minor, self-limiting, and easily resolved. Performing the inflations does require dedicated owners. Newer double-lumen tubes will be available in a wider range of balloon diameters and lengths that will expand the range of patients that can be treated. **To date only one cat has been treated and the tube inflations have been well tolerated, but long-term outcome is not yet available.** These first patients have demonstrated that the B-Tube has the potential for improved (and less expensive) outcomes in the treatment of BES as well as some RBES.

## THE B-TUBE: A GUIDE FOR PLACEMENT AND USE

### RECOMMENDED EQUIPMENT

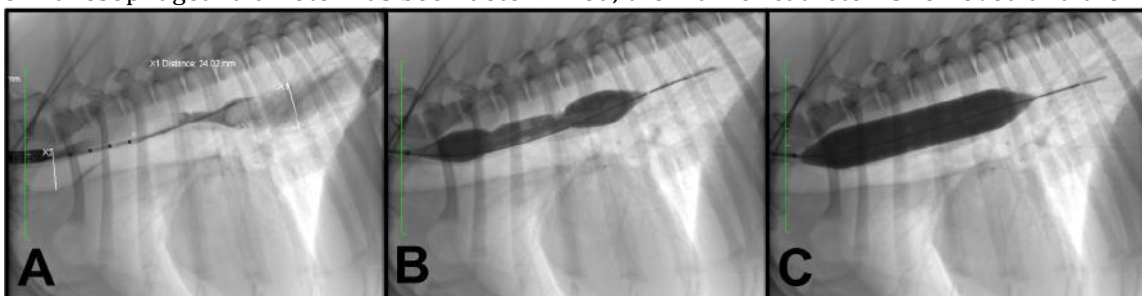- 1) Fluoroscopy and Endoscopy
- 2) Bite block/Mouth guard
- 3) Variety of standard esophageal balloon dilation catheters for initial dilation
- 4) Manual digiflator (60 mL)
- 5) Iodinated contrast agent and saline
- 6) Marker catheter with compatible guide wire
- 7) Sterile drape and small surgical pack with surgical blade
- 8) Long right---angled or Carmalt forceps
- 9) Compatible peel---away sheath (See B---Tube packaging)
- 10) Sterile 150cm 0.035" angled hydrophilic guide wire
- 11) Variety of B-Tube sizes
- 12) 2---0 or 3---0 Nylon suture for securing B-Tube
- 13) Bandage material

### PREPARATION

The patient is placed under general anesthesia and the left ventrolateral cervical region is clipped. The patient is placed in right lateral recumbency on the fluoroscopy table.

### ESOPHAGOSCOPY AND BALLOON DILATION

A mouth gag is placed and esophagoscopy is performed to identify the stricture. A 0.035" angled, hydrophilic guide wire is placed through a 5Fr marker catheter and both are advanced down the esophagus under fluoroscopic and endoscopic guidance. Once across the stricture, the guide wire is removed and a 50:50 iodinated contrast: saline mixture is injected through the marker catheter to outline the esophageal stricture and esophageal walls. Dilation of the esophagus is facilitated by air insufflation through the flexible endoscope; Dilation permits accurate measurement of the esophageal diameter. The marker catheter is used to calculate radiographic magnification. Once the normal esophageal diameter has been determined, the marker catheter is removed and the



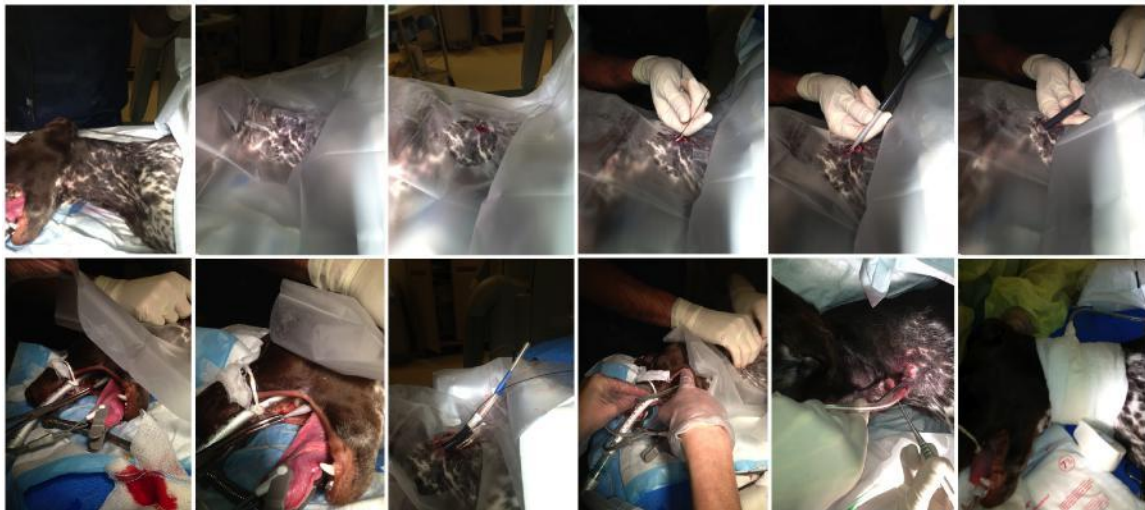appropriate esophageal balloon dilation catheter is placed alongside the flexible endoscope. A 60ml hand digiflator is filled with 50:50 iodinated contrast: saline and the balloon is inflated during

**FIGURE 3:** Serial esophageal stricture balloon dilation performed using endoscopic and fluoroscopic guidance. A. Marker catheter in place with contrast and air esophagram demonstrating stricture and maximal esophageal diameters. B. Balloon dilation demonstrating stricture dilation but not complete effacement. The lack of complete stricture effacement is often not completely appreciated endoscopically. C. Complete stricture effacement confirmed fluoroscopically.

endoscopic and fluoroscopic guidance. The use of fluoroscopy is HIGHLY recommended to confirm complete stricture effacement that may be difficult to fully discern with endoscopy alone (**FIGURE 3**). Standard esophageal balloon dilation catheters are necessary for initial stricture dilation as the B-Tube itself has a rather large profile, limiting access across some of the smaller lumen strictures. Additionally, the B-Tube tends to have less radial force than many commercially available balloon dilation catheters that are smaller diameter. Once stricture effacement has been confirmed, the balloon is deflated and removed. Endoscopic evaluation is performed to identify any complications such as full thickness esophageal tears. The distal esophagus is also fully evaluated if the endoscope was initially unable to pass through the stricture.

## B-TUBE PLACEMENT

The patient remains in right lateral recumbency and the clipped cervical region is scrubbed and prepared. A small fenestrated drape is placed over the proposed B-Tube exit site. This is chosen similarly to esophagostomy tube placements, or approximately mid-way between the angle of the mandible and thoracic inlet. For very proximal cervical esophageal strictures, the entry site may need to be more cranially located. Fluoroscopy can be helpful in identifying the cricoid cartilage and upper esophageal sphincter, and the B-Tube can enter the esophagus just caudal to the cricoid and crico pharyngeal muscle. B-Tubes have been placed as pharyngostomy tubes in extreme circumstances for strictures just caudal to the upper esophageal sphincter. Another important landmark is the jugular vein that should be identified and avoided. The appropriate B-Tube is chosen based upon previous esophageal diameter measurements and balloon dilations.

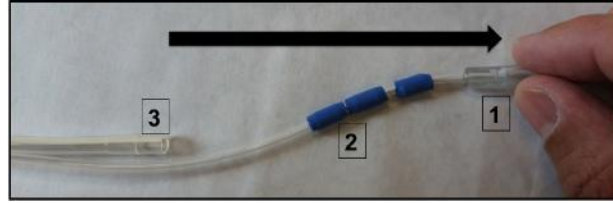


**FIGURE 4:** B-Tube placement using long right-angled forceps, 150cm angled hydrophilic guide wire, and peel-away sheath.

Placement of the B-Tube is a two-person procedure and demonstrated in **Figure 4**. The chosen B-Tube is opened in sterile fashion; A sterile field on an OR table is recommended. A 150cm 0.035" angled hydrophilic guide wire and appropriately sized peel-away sheath (see packaging for recommended sizes) are also opened in sterile fashion. The guide wire is flushed with sterile saline to provide lubrication. The B-Tube has two separate hubs on the proximal end (The feeding tube hub and the inflation tube hub, see above). The feeding tube hub is unscrewed and disconnected from the tubing in preparation for placement. At this time, you may consider trimming the distal end of the B-tube (distal to the balloon and metal marker) to minimize chances of it extending into the stomach. Additional side holes can be made as well but this is not generally necessary.

One person passes a pair of long, right-angled or Carmalt forceps trans-orally into the esophagus and positions the tip to exit at the desired B-Tube entry site. Care is taken to avoid the jugular vein and prior to an incision, the tip is palpated for any pulsations suggestive of the carotid sheath, if a pulse is

palpated, the forceps are repositioned. While the skin is gently stretched, an incision is made directly over the raised instrument tips until they exit the incision. The tips are opened and the guide wire is advanced through the incision and out the mouth. The peel-away sheath is then passed over the guide wire and advanced through the incision until it is identified in the mouth. The guide wire and dilator are removed leaving the sheath across the incision site and into the mouth. The inflation tubing hub with the three blue bands is passed retrograde through the sheath from the mouth outwards towards the incision (**FIGURE 5**). This is followed by the feeding tubing (with the hub already removed). This is generally a snug fit. Once the inflation tubing exits the sheath, it can be gently pulled until the B-Tube is across the incision, half exiting the incision and half exiting the mouth. The peel-away sheath is then removed over the tubing. The distal portion of the B-Tube containing the balloon can now be advanced down the esophagus, similar to a traditional esophagostomy tube placement procedure.

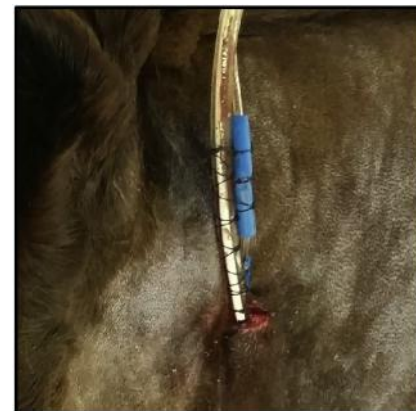

**FIGURE 5:** Hub (1) is passed retrograde through the peel away sheath first, followed by the blue compression guards (2) and then the end of the esophageal tube (3).

Fluoroscopy is used to ensure the balloon is positioned appropriately across the stricture location. The radio---opaque bands mark the most proximal and distal extent of the balloon; It is imperative the balloon does not extend across the entry site for proximal strictures. Ideally the stricture is centered across the stricture, however this is only possible in centrally located lesions. For proximal and distal strictures, it is important to have as much balloon across the stricture as possible to prevent the tube from sliding off the stricture during inflation, rather than filling above and below the lesion and expanding it during full inflation. The balloon has been placed across the lower esophageal sphincter for distal strictures; This did not appear to cause major discomfort or harm in the few patients in whom it was performed. A Sharpie can be used to mark the B-Tube at the exit site to identify the ideal location prior to suturing in place.

A dry 60cc hand digiflator is used to inflate the B-Tube balloon with air. This is performed using a 3-way stopcock and inflation is monitored under fluoroscopy. The B-tube is inflated until the balloon is uniformly expanded across the lesion and additional syringes of air do not substantially add to the balloons diameter as evaluated with fluoroscopic visualization. The total number of 60cc syringes of air is then determined (Ranging from ~1 full syringes (cat) for the smallest B-Tube to approximately 6 or more syringes for the largest B-Tubes).

Once the positioning has been confirmed, the inflation tubing can be “peeled” off the feeding tubing, and the feeding tube can be trimmed to an appropriate length. The inflation tubing cannot be trimmed. The two individual tubes are separated down to the entry site and each are sutured individually to the skin. The feeding tubing is sutured with a 3-0 or 2-0 nylon purse-string (loose to avoid pressure necrosis) and finger-trap suture pattern. The inflation tubing is also sutured with a purse-string and finger-trap technique, however the blue compression guards must be used; otherwise the finger-trap sutures would compress the inflation tubing and prevent inflation of the balloon (**FIGURE 6**). After secured in place, the feeding tubing is trimmed and the hub is replaced.



**FIGURE 6:** Finger-trap securing the tubing. Note the sutures on in the inflation tubing are tied around the blue compression guards to prevent compression of the relatively narrow tubing.

The B-tube is wrapped as is typical for esophagostomy tubes, using a small amount of triple antibiotic ointment, non-adherent gauze, cast padding and outer

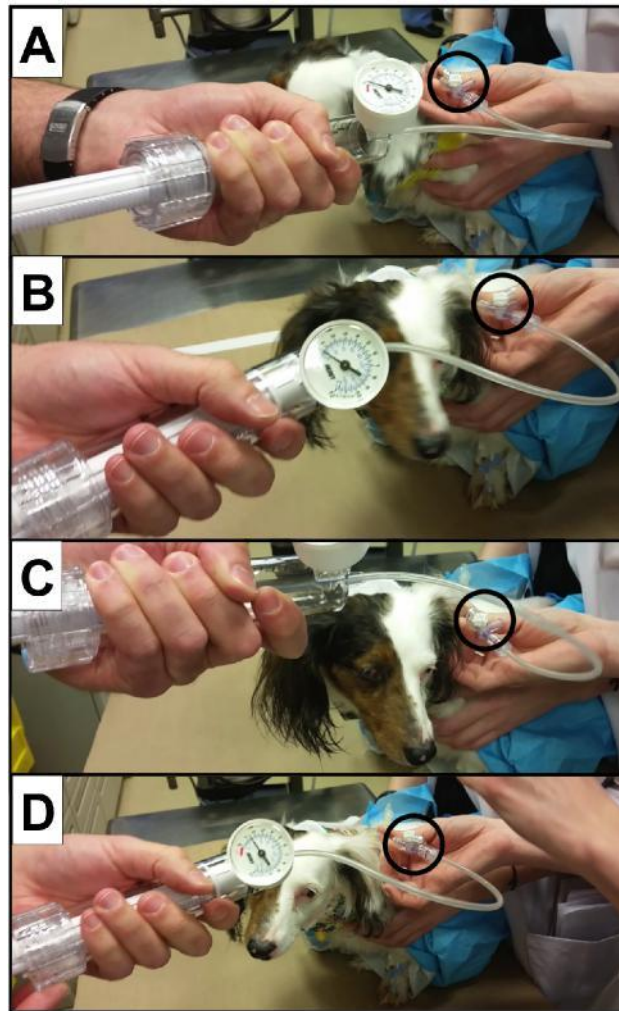
wrapping. The patient is recovered and water is offered per os later that night; Per os feeding is not initiated for 12 to 24 hours, rather the feeding tubing is used for medications and liquid feeding. A post-placement radiograph may be indicated to confirm placement prior to the first inflation if there are any concerns.

The patient is often hospitalized overnight for monitoring. The veterinarian should perform an awake dilation prior to patient discharge. The veterinarian should also watch the clients perform a dilation procedure to confirm they are doing it appropriately (see below). Standard discharge medications include proton-pump inhibitors (such as omeprazole) and gastric mucosal barrier protectant (such as sucralfate).

## DILATION PROCEDURES

Performing balloon dilation in the awake patient is typically a two person job; One to work the three-way stopcock and the other to handle the manual digiflator (**FIGURE 7**). When possible, a third person to hold the patient is ideal. An extra B-Tube should be available to train the clients on the inflation procedure before attempting in the patient. The veterinarian should watch the clients perform the procedure multiple times before they attempt the procedure themselves. In order to perform the inflation, follow the order below.

- 1) Remove the injection caps on the stopcock that remain in place when the B-Tube is not in use.
- 2) Attach the manual digiflator as demonstrated in Figure 7.
- 3) With the stopcock "Off to patient" as in **Figure 7A**, fill the digiflator with air.
- 4) Turn the stopcock "Off to atmosphere" and inflate the B-Tube (**Figure 7B**).
- 5) Turn the stopcock "Off to patient" in order to refill the digiflator with air (**Figure 7C**).
- 6) Repeat steps (4) and (5) until you have inflated to B---Tube with the previously determined amount of air during Tube placement.
- 7) When performing the final syringe inflation, immediately after the syringe of air has been administered, turn the stopcock "Off to digiflator" (**Figure 7D**). A release of air will be heard escaping from the B-tube and exiting the stopcock.
- 8) Turn the stopcock "Off to atmosphere" and evacuate the B-Tube of any remaining air to maintain a low-profile tube within the esophagus.
- 9) Turn the stopcock "Off to patient", disconnect the digiflator, and reattach the injection caps. The inflation procedure is finished.



**FIGURE 7:** The B-Tube inflation procedure. The black circles indicate the position of the stopcock during the different steps of balloon inflation.

The clients should be warned that the inflations could cause some gagging. This resolves as soon as the balloon is deflated. There is no need to maintain balloon dilation for any period of time; simply fill the balloon and immediately deflate it. Balloon inflations continue twice daily for 4-6 weeks until removal. While the feeding tube portion of the B-Tube can be used for nutritional supplementation, the clients are encouraged to feed to patient progressively thickened gruels, canned food, and dry kibble over time to encourage esophageal functioning.

## B-TUBE REMOVAL

In general, B-Tube removal is performed under general anesthesia to facilitate removal as well as to repeat endoscopy to characterize the status of the stricture. During endoscopy, it is not uncommon to see some esophageal irritation along the length of the B-Tube due to chronicity. In most cases performed to date, the B-Tube could have been removed in the awake patient simply by cutting the purse-string sutures and gently pulling the tube out. In some patients, the B-Tube balloon may be too large to easily pass through the exit site. This necessitates cutting of the tube, pushing it into the esophagus, and retrieving the tube in the esophagus with an endoscope and snare or graspers. After removal, a light neck wrap is placed over the exit site and removed in one or two days. Proton-pump inhibitors and gastric mucosal barrier medications are continued for 2-4 weeks as needed.

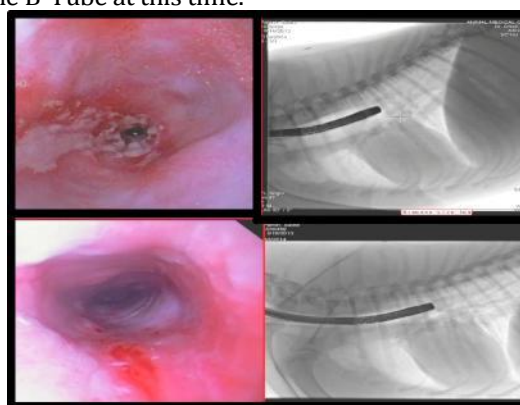
## TROUBLE-SHOOTING

Problems during tube placement are uncommon but can theoretically include nausea, regurgitation, vomiting, hub loosening, exit site irritation/infection, and anorexia. Repeat radiographs can confirm proper B-Tube placement when compared those taken post-tube placement originally. If there is any increased discomfort experienced by the patient during inflation, the clients should be instructed to abort the inflation procedure and have the patient evaluated by the veterinarian immediately. If the client finds that the B-tube inflations become very easy (no resistance encountered during inflation likely due to a ruptured balloon), the patient should be evaluated immediately. No major complications have been encountered with the use of the B-Tube at this time.

## PRELIMINARY DATA

Initial results have been presented<sup>19</sup> and are encouraging.

Five female spayed and 1 male castrated dog ranging from 8 months to 7 years with confirmed esophageal strictures were included in this preliminary study (**TABLE 1**). Causes for the strictures were confirmed following OHE surgery in 2, dental prophylaxis in 1, parvovirus infection in 1, IVDD surgery in 1, and suspected due to nausea following hydroxyurea therapy for polycythemia vera in 1. At the time of EBDFT placement, these patients received between 1 and 10 previous esophageal balloon dilations; 2 of which were considered recurrent (RBES) (>3 previous dilations). Prior to EBDFT placement, 5 dogs had dysphagia scores of 3/4 (only able to swallow liquids) and 1 had a score of 2.5/4 (able to tolerate gruels but continued to regurgitate).



**FIGURE 8:** Endoscopic (left) and fluoroscopic (right) images during initial stricture evaluation at the time of EBDFT placement (above) and following removal of the EBDFT approximately 5 weeks later. Although there is some esophageal irritation from the chronic presence of the EBDFT in the bottom endoscopic image, complete stricture resolution is documented. This patient returned to normal eating (dysphagia score 3/4 pre-op to 0/4 following tube removal).

All patients had endoscopic and fluoroscopic guided balloon dilation of the strictures as well as esophagoscopy before and after EBDFT placement. Five dogs had EBDFT placement via esophagostomy and one dog received pharyngostomy placement due to the proximal stricture location. There were no major intra-operative complications. All patients were discharged the same or the following day.

Post-operative complications occurred in 2 dogs including premature tube removal by the dog (1), and EBDFT failure requiring exchange (1). Two additional dogs had minor irritation or local infection at the tube sites that improved with cleaning and oral antibiotics. The prematurely removed tube was vomited up, presumably due to the location of the tube entering the stomach secondary to the very distal location of the stricture; this patient's final dysphagia score was 1/4 (able to swallow some kibble and canned food) following removal, and esophagoscopy demonstrated only a mild esophageal narrowing remaining. The EBDFT failure patient was ultimately euthanized due to severe comorbidities including polycythemia vera and other undiagnosed disease processes. Tubes remained in place between 14 and 56 days (**FIGURE 8**); Follow-up times ranged from 14 to 753 days (median 161 days, mean 274 days). Five of 6 dogs had improved dysphagia scores compared to pre-operative measurements (**TABLE 1**) and the sixth was ultimately euthanized due to comorbidities. While balloon inflations caused apparent minor, temporary discomfort in most patients, the owners felt it was well tolerated and instantaneously resolved following balloon deflation.

### Dysphagia Score Sheet

A previously described and commonly used human "dysphagia score" of 0-4 was modified and used to determine outcome.

Score 0: Patients able to eat a normal diet with no dysphagia.  
 Score 1: Patients able to swallow some solid foods (kibble or canned food).  
 Score 2: Patients able to swallow only semi-solid foods (gruel).  
 Score 3: Patients able to swallow liquids only.  
 Score 4: Patients unable to swallow anything including saliva; total dysphagia.

A **DECREASE** in dysphagia score is considered a clinical improvement.

Case	Signalment	Cause	Previous Dilations	PRE-Dysphagia Score (0-4)	POST-Dysphagia Score (0-4)
1	8mon GSHP	OHE	2	3	1
2	11mon Gldn-Doodle	OHE	4	3	0
3	2yo LABR	Meds*	1	3	N/A
4	7yo LABR	Dental	10	3.5	2.5
5	2yo Chi	Parvo	1	2.5	0
6	5yo Dach	IVDD Sx	1	3	0

**TABLE 1:** Table demonstrating patient signalment, stricture etiology, number of previous balloon dilations performed prior to EBDFT placement, pre-EBDFT dysphagia score, and final dysphagia score at last follow-up. \*Patient 3 was euthanized for other comorbidities prior to the EBDFT removal so a final dysphagia outcome could not be determined.

Initial results suggest that the EBDFT can be an effective, single-procedure alternative to repeated balloon dilation procedures for the treatment of benign esophageal strictures in dogs. Preliminary results indicate complications including insertion site irritation/infection, inflation discomfort, and early tube failure (repaired) are relatively minor, self-limiting, and easily resolved. Performing the inflations does require dedicated owners. While there are certain size limitations currently, early prototypes have been updated. Newer double-lumen tubes will be available in a wider range of balloon diameters and lengths that will expand the range of patients that can be treated.

These first patients have demonstrated that the EBDFT has the potential for improved (and less expensive) outcomes in the treatment of BES as well as some RBES.

**VIDEO OF B-TUBE PLACEMENT**  
[youtube.com/watch?v=aXiGIZMxd7k](https://www.youtube.com/watch?v=aXiGIZMxd7k)

## REFERENCES AND SUGGESTED READING

1. Adamama-Moraitou K.K., Rallis T.S., Prassinis N.N., et al. Benign esophageal stricture in the dog and cat: a retrospective study of 20 cases. *Can J Vet Res* 2002 66; 55-9.
2. Battersby I, Doyle R. *J Small Anim Pract*. Use of a biodegradable self-expanding stent in the management of a benign oesophageal stricture in a cat. 2010;51:49-52.
3. Bissett SA, Davis J, Subler K, et al. Risk factors and outcome of bougienage for treatment of benign esophageal strictures in dogs and cats: 28 cases (1995–2004). *J Am Vet Med Assoc* 2009;235:844–850.
4. Dua, KS. Expandable stents for benign esophageal disease. *Gastrointest Endoscopy Clin N Am*. 2011; 21: 359–376.
5. Glanemann B, Hildebrandt N, Schneider MA, Moritz A, Neiger R. Recurrent single oesophageal stricture treated with a self-expanding stent in a cat. *J Feline Med Surg*. 2008;10:505-9.
6. Glazer A, Walters P. Esophagitis and esophageal strictures. *Compend Contin Educ Vet*. 2008;30:281-92.
7. Hansen KS, Weisse C, Berent AC, Dunn M, Caceres AV, Todd KL, Diroff JS. Use of a self-expanding metallic stent to palliate esophageal neoplastic obstruction in a dog. *J Am Vet Med Assoc*. 2012;240:1202-7.
8. Harai BH, Johnson SE, Sherding RG. Endoscopically guided balloon dilatation of benign esophageal strictures in 6 cats and 7 dogs. *J Vet Intern Med* 1995;9:332–335.
9. Hirdes MM, Siersema PD, van Boeckel PG, Vleggaar FP. Single and sequential biodegradable stent placement for refractory benign esophageal strictures: a prospective follow-up study. *Endoscopy*. 2012;44:649-54.
10. Holm AN, de la Mora Levy JG, Gostout CJ, Topazian MD, Baron TH. Self-expanding plastic stents in treatment of benign esophageal conditions. *Gastrointest Endosc*. 2008;67:20-5.
11. Kochman ML, McClave SA, Boyce HW. The refractory and the recurrent esophageal stricture: a definition. *Gastrointest Endosc* 2005;62:474-5.
12. Leib MS, Dinnel H, Ward DL, et al. Endoscopic balloon dilation of benign esophageal strictures in dogs and cats. *J Vet Intern Med*. 2001;15:547–552.
13. Mellow MH, Pinkas H. Endoscopic laser therapy for malignancies affecting the esophagus and gastroesophageal junction. Analysis of technical and functional efficacy. *Arch Intern Med*. 1985; 8:1443-6
14. Melendez LD, Twedt DC, Weyrauch EA, et al. Conservative therapy using balloon dilation for intramural, inflammatory esophageal strictures in dogs and cats: a retrospective study of 23 cases (1987–1997). *Eur J Comp Gastroenterol* 1998;3:31–36.
15. Repici A, Conio M, De Angelis C, et al. Temporary placement of an expandable polyester silicone-covered stent for treatment of refractory benign esophageal strictures. *Gastrointest Endosc* 2004;60:513-9.
16. Siersema PD, de Wijkerslooth LR. Dilation of refractory benign esophageal strictures. *Gastrointest Endosc*. 2009;70:1000-12.
17. Siersema PD. Stenting for benign esophageal strictures. *Endoscopy*. 2009;41:363-73.
18. van Boeckel PG, Vleggaar FP, Siersema PD. A comparison of temporary self-expanding plastic and biodegradable stents for refractory benign esophageal strictures. *Clin Gastroenterol Hepatol*. 2011;9:653-9.
19. Weisse C, Berent A. Prospective evaluation of a one-stage esophageal balloon dilation feeding tube (EBDFT) for benign esophageal strictures: Initial results in 6 dogs. *ACVIM* 2015, Indianapolis, IN.